Mandibular Osteoradionecrosis

Dick Clarke, CHT

Mandibular Osteoradionecrosis

Review & Update

Primary Training in Hyperbaric Medicine
Columbia, South Carolina

"Late radiation tissue injury is a sign of success"

Sanders M, Dische S.
2002 ESTRO Meeting, Prague

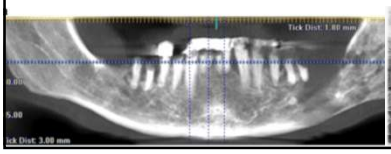

Radiation tissue injury; "non-target" tissues

Acute effects: *DNA damage, cell death-rapidly proliferating cells*

self-limiting +/- RT pause

Late effects: *chronic oxidative stress*

dose-dependent > complex wounds/organ loss

"consequential vs. generic"



CLINICAL SCIENCES

411-109

Osteoradionecrosis of the Jaws: A Retrospective Study of the Background Factors and Treatment in 104 Cases

MARCOS MARTINS CURI, DDS,* AND LUCIANO LAURIA DIB, DDS, PhD†

Purpose: This study analyzed potential risk factors in patients who received radiotherapy for head and neck cancer and developed osteoradionecrosis.

Patients and Methods: A group of 104 patients who developed osteoradionecrosis of the jaws were retrospectively treated between 1972 and 1990. Primary sites were oral cavity (50 patients), oropharynx (29 patients), nasopharynx (15 patients), larynx (5 patients), paranasal sinuses (2 patients), and unknown primary (3 patients). Tobacco and alcohol were implicated in 94 (90.4%) patients. Mandibular involvement was observed in 90 (86.5%) patients, maxillary involvement in 14 (13.5%) patients, and both jaws in 4 (3.8%) patients. Bone exposure was observed in 90 (86.5%) patients, fistulas in 14 (13.5%) patients, and pathological fracture in 4 (3.8%) patients. Mean time from radiation therapy until the beginning of ORN was 3 years (range, 1 month–20 years). Mean time from tooth extraction until the beginning of ORN was 2 years (range, 1 month–10 years). Mean time from the beginning of ORN until the end of treatment was 2 years (range, 1 month–10 years). Mean time from the beginning of ORN until the last follow-up was 4 years (range, 1 month–20 years). Mean total radiation dose was 6,000 cGy (range, 1,000–7,400 cGy). Mean total radiation dose in patients who developed ORN was 6,000 cGy (range, 1,000–7,400 cGy). Mean total radiation dose in patients who developed ORN without extraction was 5,000 cGy (range, 1,000–7,400 cGy). Mean total radiation dose in patients who developed ORN with extraction

211-067
CLINICAL ARTICLES

Osteoradionecrosis:
A New Concept of Its Pathophysiology

ROBERT E. MARX, DDS*

Marx RE, J Oral Maxillofac Surg 1983;41:283-288

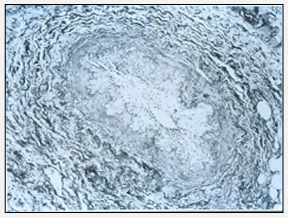

CLINICAL ARTICLES
211-068

A New Concept in the Treatment of Osteoradionecrosis

ROBERT E. MARX, DDS*

Marx RE, J Oral Maxillofac Surg 1983;41:351-357

Marx ORN Protocol

Stage I. HBO as primary therapy

Stage II. Indication for surgery post-HBO
~ *sequestrectomy*

Stage III. Mandible resection/fixation

Stage III-R. Mandible reconstruction

Classification Methods and Staging Systems for Osteoradionecrosis of the Mandible

Investigators		Grading Systems	
Marx RE.	**A new concept in the treatment of osteoradionecrosis.** *J Oral Maxillofac Surg 1983;41:351-7*	Stage I:	30 dives of HBO used to attain mucosa recovery
		Stage II:	Grade I non-responders who need transoral alveolar sequestrectomy
		Stage III:	Grade II non-responders; a bone resection needed
		Stage III-R:	An additional 30 dives of HBO given to patients who needed a bone graft
Coffin F.	**The incidence and management of osteoradionecrosis of the jaws following head and neck radiotherapy.** *Br J Radiol 1983;56:857*	Minor:	Small sequesters that may separate spontaneously over several weeks
		Major:	Bone necrosis extending to the entire thickness of the jaw; pathological fracture sometimes present
Morton ME.	**Osteoradionecrosis: a study of the incidence in the North West of England.** *Brit J Oral Maxillofac Surg 1986;24:323-31*	Minor:	Bone exposure with ulceration and a history of spontaneously resolving bony spicules
		Moderate:	Small sequester limited in nature and resolving spontaneously
		Major:	Large area of exposed bone and sequester; bone fracture and fistula
Epstein JB, *et al.*	**Osteoradionecrosis: clinical experience and a proposal for classification.** *J Oral Maxillofac Surg 1987;45:104-10*	Stage I:	Resolved/healed, with or without pathological fracture
		Stage II:	Chronic/persistent non-aggressive, with or without pathological fracture
		Stage III:	Active/progressive, with or without pathological fracture
Urken ML, *et al.*	**Oromandibular reconstruction using microvascular composite free flaps.** *Arch Otolaryngol Head Neck Surg 1991;117(3):733-744*		Based upon anatomic, functional and aesthetic considerations ORN as a function of location within mandible; symphysis, body, ramus and condyle.
Glanzmann C, Gratz KW.	**Radionecrosis of the mandibular: a retrospective analysis of the incidence and risk factors** *Radiother Oncol 1995;38:94-100*	Stage 1:	Bone exposure without signs of infection and persisting for at least 3 months
		Stage 2:	Bone exposure with infection or sequester and without the signs of stage 3-5
		Stage 3:	Bone necrosis treated with mandibular resection with a satisfactory result
		Stage 4:	Bone necrosis treated with mandibular resection with a satisfactory result
		Stage 5:	Death due to ORNJ
Clayman L.	**Clinical controversies in oral and maxillofacial surgery: part two. Management of dental extractions in irradiated jaws: a protocol without hyperbaric oxygen therapy.** *J Oral Maxillofac Surg 1997;55:275-81*	Type I:	Presenting with bone lysis under intact gingiva or mucosa
		Type II:	Bone exposure with secondary contamination; an aggressive form
Wong JK, *et al.*	**Conservative management of osteoradionecrosis** *Oral Surg Oral Med Oral Path Oral Radiol Endod 1997;84:16-21*	Stage 1:	Bone exposure resulting from tumor necrosis where tumor death results in a loss of soft tissue coverage
		Stage 2:	Bone exposure as a consequence of tumor recurrence
		Stage 3:	Bone exposure resultant from oral surgical (surgical lavage operations) or other dental interventions including dental treatment
		Stage 4:	Bone exposure de novo without apparent cause aside from radiation exposure
Stone G, Boysen M.	**Mandibular osteoradionecrosis: clinical behavior and diagnostic aspects.** *Clin Otolaryngol Allied Sci 2000;25:378-84*	Stage 0:	Mucosa defect only
		Stage I:	Radiological evidence of necrotic bone with intact mucosa
		Stage II:	Positive radiographic findings with denuded bone intraorally
		Stage III:	Exposure of the necrotic bone; skin fistula and infection
Schwartz HC, Kagan AR.	**Osteoradionecrosis of the mandible: scientific basis for clinical staging.** *Am J Clin Oncol 2002;25:168-71*	Stage I:	Superficial involvement of the mandible only
		Stage II:	Localized involvement of the mandible, with or without soft tissue necrosis
		Stage III:	Diffuse involvement of the mandible, with or without soft tissue necrosis
Notani K, *et al.*	**Management of mandibular osteoradionecrosis corresponding to the severity of osteoradionecrosis and the method of radiotherapy.** *Head Neck 2003;25:181-6*	Stage I:	ORN confined to alveolar bone
		Stage II:	ORN limited to the alveolar bone and/or above the level of the inferior alveolar canal
		Stage III:	ORN under the lower part of the inferior alveolar canal, with fistula or bone fracture
Tsai CJ, *et al.*	**Osteoradionecrosis and radiation dose to the mandible in patients with oropharyngeal cancer.** *Int J Radiat Oncol Biol Phys 2013;85:415-20*	Stage I:	Minimal bone exposure with conservative management only
		Stage II:	Minor debridement required
		Stage III:	HBO needed
		Stage IV:	Major surgery needed
Karagozoglu KH, *et al.*	**Management of mandibular osteoradionecrosis corresponding to the severity of osteoradionecrosis and the method of radiotherapy.** *Med Oral Patol Oral Cir Bucal 2014;19:e433-7*	Stage 0:	Bone exposure more than 1 month; no distinct changes on imaging
		Stage I:	Bone exposure with no distinct changes on imaging, with or without symptoms
		Stage II:	Bone exposure with distinct changes on imaging, with no involvement of the lower mandible border
		Stage III:	Necrotic bone involving the lower border of the mandible
Lyons A, *et al.*	**Osteoradionecrosis—a review of current concepts in defining the extent of the disease and a new classification proposal.** *Br J Oral Maxillofac Surg 2014;52:392-5*	Stage 1:	<2.5 cm length of bone affected; asymptomatic
		Stage 2:	>2.5 cm length of bone affected; involving fracture or the inferior dental nerve
		Stage 3:	>2.5 cm length of bone affected; symptomatic, with no other features
		Stage 4:	>2.5 cm length of bone affected; bone fracture and involving inferior dental nerve or fistula
Bone/soft tissue		**Classification**	
He Y, *et al.*	**Retrospective analysis of osteoradionecrosis of the mandible: proposing a novel clinical classification and staging system.** *Int J Oral Maxillofac Surg 2015;44:1547-1557*	B0:	No distinct changes or just osteolytic images on radiography, but patients suffering from typical ORNM-related symptoms (bone exposure or pain)
		B1:	Maximal diameter of the lesion on radiography <2.0 cm
		B2:	Maximal diameter of the lesion on radiography ≥ 2.0 cm
		B3:	Pathological fracture
Soft tissue defect (S)		S0:	Mucosal and skin integrity
		S1:	Intraoral mucosal defect or external skin fistula
		S2:	Intraoral mucosal and external skin defect; through-and-through defect
		Stage 0:	Conservative therapy
		Stage I:	Sequestrectomy and primary closure
		Stage II:	Marginal resection without reconstruction, or segmental resection combined with osteocutaneous flap reconstruction; an additional soft tissue flap should be used in patients with an orocutaneous fistula
		Stage III:	Segmental resection combined with osteocutaneous flap reconstruction; an additional soft tissue flap should be used in patients with an orocutaneous fistula

Radiation damaged tissue as a unique wound

BEAM PROFILE

The dose variation across the field at a specified depth.

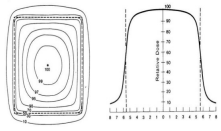

Regulation of wound-healing angiogenesis—Effect of oxygen gradients and inspired oxygen concentration

Knighton DR, *et al.* Surgery 1981;90(2)

1.0 ATA air

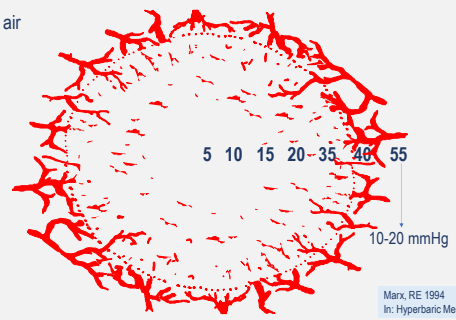

Marx, RE 1994
In: Hyperbaric Medicine Practice

HBO at 2.4 ATA

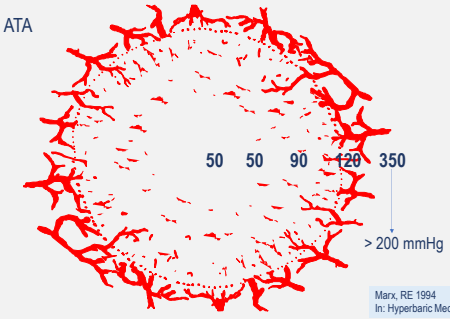

Marx, RE 1994
In: Hyperbaric Medicine Practice

Rapid rise phase

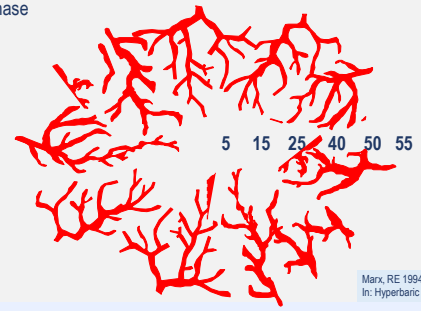

Marx, RE 1994
In: Hyperbaric Medicine Practice

Plateau Phase

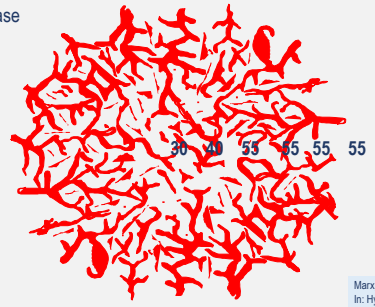

Marx, RE 1994
In: Hyperbaric Medicine Practice

Vascular density change over time

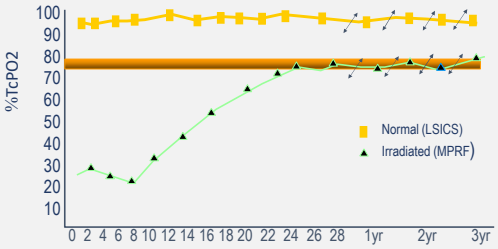

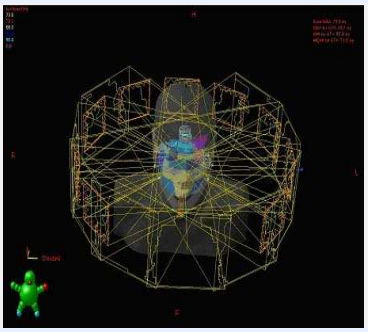

Micro-angiogenic vascular density

	Normobaric Air (N=7)	Normobaric Oxygen (N=14)	Hyperbaric Oxygen (N=14)
Maximum VDE	18	19	99
Minimum VDE	6	6	78
Mean VDE	13	13	93

Normobaric air vs. Normobaric O_2 $p < 0.89$
Normobaric O_2 vs. Hyperbaric O_2 $p < 0.01$
Normobaric air vs. Hyperbaric O_2 $p < 0.01$

Marx RE, *et al.* 1990
Am J Surgery; 160

1.0 ATA air | 1.0 ATA oxygen | 2.5 ATA oxygen

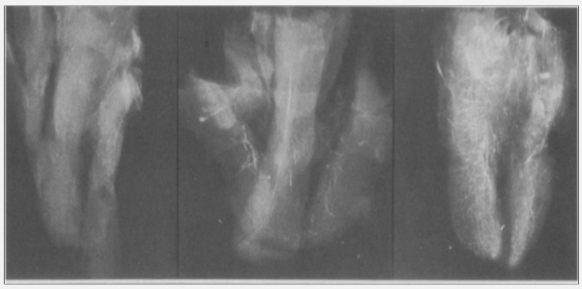



Effect of hyperbaric oxygen treatment on oxygen tension and vascular capacity in irradiated skin and mucosa

Clinical Pathology
Clinical Paper

20 pts hx H/N RT 50-70 Gy.
ORN or ORN prophylaxis

Randomly allocated HBO vs. no-HBO

Skin & mucosal tissue perfusion measurements
Transcutaneous oximetry & Doppler flowmetry

pre-HBO & 6 months post-HBO
controls 6 months apart

Svalestad J, *et al.* Int J Oral Maxillo Surg 2014;43

$tcpO_2$ measurements pre/post HBO vs. controls

		HBO group Baseline	3 months	6 months	Controls Baseline	6 months
Forehead	*Basal*	39.8 +/-15.75	39.87 +/-11.25	41.3 +/-10.5	41.3 +/-12	43.6 +/-10.5
	O_2	140.3+/-71.3	135.8 +/-37.5	137.3 +/-38.3	127.5 +/-55.5	113.3 +/-39.8
Cheek	*Basal*	29.3 +/-13.5	42.8 +/-15.7 *	42.8 +/-7.5 *	31.5 +/-9	29.3 +/-11.3
	O_2	105.0 +/-43.5	150.85 +/-63.8 *	148.5 +/-48.8 *	105.0 +/-37.5	95.3 +/-34.5
Intercostal	*Basal*	54.0 +/-13.5	54.8 +/-15	59.3 +/-9.75	64.5 +/-18	62.3 +/-14.3
	O_2	148.2 +/-52.5	156.8 +/-52.5	156.8 +/-43.5	116.3 +/-33	145.5 +/-45.0

** $P < 0.05$ compared to baseline*



Effect of hyperbaric oxygen treatment on irradiated oral mucosa: microvessel density

Research Paper
Head and Neck Oncology

Same 20 pts hx H/N

Buccal oral mucosa tissue samples

pre-HBO & 6 months post-HBO

controls 6 months apart

Svalestad J, *et al.* Int J Oral Maxillo Surg 2015;44

Vascularization & cell proliferation

Blood vessels	HBO Group Baseline	6 months	p	Controls Baseline	6 months	p
Sub-epithelial						
MVD	45.4 +/- 13.9	98.0 +/- 15.9	0.002	45.6 +/- 15.7	49.3 +/- 10.5	NS
MVA	1.5 +/- 0.6	4.4 +/- 1.9	0.003	1.5 +/- 0.6	1.6 +/- 0.5	NS
Deeper connective tissue						
MVD	30.4 +/- 10.1	45.1 +/- 16.4	0.01	28.1 +/- 9.6	34.4 +/- 7.8	NS
MVA	2.5.+/- 1.3	3.7 +/- 1.3	0.041	2.2 +/- 0.9	2.7 +/- 1.4	NS
Lymph vessels						
Sub-epithelial						
MVD	18.3 +/- 8.1	36.1 +/- 12.6	0.002	19.4 +/- 6.2	16.9 +/- 8.8	NS
MVA	1.3 +/- 0.7	2.7 +/- 1.8	0.019	1.2 +/- 0.6	1.5 +/- 0.7	NS

Marx ORN protocol

Marx Stage I: Localized/early disease

30 HBO treatments

Stage I responder

decreased amount of exposed bone

resorption or spontaneous sequestration

softening of exposed bone

211-472

CLINICAL INVESTIGATION — **Normal Tissue**

COMPLETE RESTORATION OF REFRACTORY MANDIBULAR OSTEORADIONECROSIS BY PROLONGED TREATMENT WITH A PENTOXIFYLLINE-TOCOPHEROL-CLODRONATE COMBINATION (PENTOCLO): A PHASE II TRIAL

Sylvie Delanian, M.D., PhD.,* Christel Chiche, D.D.S.,† Hassan Poisvin, Ph.D.,‡ Jean Dhermet, M.D., Ph.D.,‡ and Jean-Louis Lefaix, Ph.D.*

*Service d'Pre-Malade Hôtel-Dieu, and †Département de Stomatologie et Orthodontie de Saint-Louis, AP-HP, Paris, ‡Biostatistique, Institut Gustave-Roussy, Villejuif, §Service de Chirurgie Cervico-Faciale, Hôpital Tenon, AP-HP, Paris, and ¶CLICAN Centre Régional de Lutte Contre le Cancer, Bordeaux, France

Purpose: Osteoradionecrosis (ORN) is a misleading consult of the bone that is difficult to manage. Conventional treatment, pentoxifylline and vitamin E, achieves radiohistological fibrosis and ORN only in a good prognosis. We previously showed that the combination of pentoxifylline and vitamin E with clodronate (PENTOCLO) is useful in patients with ORN refractory to conventional treatment. The aim of this study was to confirm this.

Methods: 10 eligible patients previously irradiated for head and neck cancer having ORN stage 2 or more (previously treated conservative mandibular ORN for 1.4 ± 1.8 years, mainly after local surgery and hyperbaric oxygen treatment) were treated with PENTOCLO for 6 months. Clinical, radiological, and the mean Subjective, Objective, Management, and Analytic evaluation of injury (SOMA) score (see Ref. 1 in Reference Section) 2000 and August 2005, all patients were given daily oral PENTOCLO, 800 mg pentoxifylline, 400 mg vitamin E, and 1 mg clodronate. Clinical, radiological, and SOMA evaluations were made every 2 months. Significant ORN improvement was defined as a decrease of at least 2 points in the SOMA score, and complete healing was defined as a SOMA score of 0. The duration of treatment was related to consolidated healing.

Results: Mean SOMA score decreased significantly (p = 0.0001) from 7.5 ± 1.5 to 2.5 ± 2.5 (range, 0–7). Clinical improvement (SOMA decrease ≥ 2) was achieved in 9 patients, and significant (p = 0.0001) reduction of exposed bone (R), respectively 2.5 ± 1.5 to 0.5 ± 1.5 (range, 0–5). Mean R was 0 in 5 patients. Complete healing was observed in 4 patients, and partial recession in 5 patients. All patients experienced complete recovery in a median of 9 months. Clinical improvement was measured in terms of desensitization of analgesics, new fractures, closed skin fistulas, and delayed healing after dentoalveolar surgery. No ORN relapse occurred.

Conclusion: PENTOCLO treatment reduces, and, and cures in the refractory ORN and radiation-induced fibrosis, yielding with significant symptom improvement. These findings will need to be confirmed in a controlled clinical trial. © 2006 Elsevier Inc.

Protocol Date. Alpha irradiation, Clodronate, Osteoradionecrosis, Radiotherapy.

INTRODUCTION

Mandibular osteoradionecrosis (ORN) is a delayed injury induced by ionizing radiation, mostly after treatment for malignant tumors of the head and neck. Because ORN can be very disfigurating and compromise functional prognosis. Although conformal radiotherapy (RT) is improving the therapeutic ratio, it has reduced the incidence of severe complications. ORN is still unpredictable (in recent 19% of cases, especially after dentoalveolar extraction, mostly 6–months to 5 years after irradiation) (1). Mandibular ORN symptoms, excluding tumor recurrence, are: 1) Pain, 2) Bone exposure, 3) Spontaneous or dentoalveolar fistula with soft tissue necrosis and spontaneous complications like osteomyelitis, fractures, and fistulas (2). Multiple risk factors have been reported, including patient and treatment factors, including radiotherapy (dose, volume, fractionation), surgery (number, volume, hemostasis, infection), and

Supported by the Délégation à la Recherche Clinique of the Assistance Publique-Hôpitaux de Paris.

Conflict of interest: none.

Acknowledgment. The authors thank Charles Gardner and physiotherapist Jacqueline Jeanneau-Lefebvre for extending their patients to us for treatment.

Received Oct. 2, 2006, and Accepted Jan. 2008. Accepted for publication March 25, 2008.

Delanian S, *et al.* Int J Rad Oncol Biol Phys 2011

PENTOCLO

Pentoxifylline - Tocopherol - Clodronate

PENTO

Pentoxifylline - Tocopherol

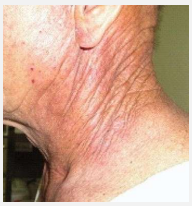

Oral & Maxillofacial Surgery

211-438

Systematic Review and Meta-Analysis

Clinical Pathology

Management of osteoradionecrosis of the jaws with pentoxifylline–tocopherol: a systematic review of the literature and meta-analysis

A. Kolokythas, J. T. Thomason, J. Rourke, C. Fung, Management of osteoradionecrosis of the jaws with pentoxifylline–tocopherol: a systematic review of the literature and meta-analysis. Int J Oral Maxillofac Surg. 2019; 48: 273–280. © 2018 International Association of Oral and Maxillofacial Surgeons. Published by Elsevier Ltd. All rights reserved.

Abstract. Osteoradionecrosis (ORN) of the jaws remains among the most commonly encountered and challenging complications of radiotherapy to the head and neck. Pentoxifylline–tocopherol (PENTO) has been used in the management of patients with ORN and evaluate the reported outcomes with the use of pentoxifylline and tocopherol (PENTO), by means of a systematic review and meta-analysis. The primary outcome was ORN healing, and secondary outcomes of the review and meta-analysis was the proportion of full recovery, or significant improvement, after requiring further intervention. The likelihood function was used to combine the studies and estimate the pooled and standard deviation of each outcome by the maximum likelihood estimation. Seven studies met the inclusion criteria. A total of 1 patients with ORN treated with PENTO underwent a meta-analysis. The overall improved significantly not requiring further intervention. Sixty patients initiated the same. 19 were lost to follow-up, and the disease progressed in 14. The current evidence suggests that PENTO is a promising treatment option for patients with ORN. Additional well-designed prospective studies are needed in order to further validate the regimens that can then be employed in the treatment of ORN.

Key words: ORN. PENTO. medical management. systematic review. meta-analysis.

Accepted for publication: Available online 8 September 2018

Osteoradionecrosis (ORN) of the jaws remains among the most commonly encountered complications of radiotherapy to the head and neck, even in the era of intensity modulated radiotherapy (IMRT). Its incidence in the literature has been reported variably, ranging from 2% up to 22%, and although it is considered a late event, the vast majority of cases occur within the first 3 years after radiotherapy. The aetiology is multifactorial, but the result of an insult to the underlying bone (i.e., either an ex-

Kolokythas A, *et al.* Int.J. Oral & Maxillofac Surg.2019; 48

211-462

Vol. 129 No. 3 March 2020

The effect of combined application of pentoxifylline and vitamin E for the treatment of osteoradionecrosis of the jaws: a meta-analysis

Zhara Zhang, MDS, Weiwei Xiao, MDS, Yongjia Xu, MDS, Yanni Chen, MDS, Chunlin Zong, DDS, Lu Zhao, MDS, and Lei Tian, MD, DDS

Objective. The aim of this study was to evaluate the effect of combined application of pentoxifylline and vitamin E (PENTO) for the treatment of osteoradionecrosis of the jaws (ORNJ) by performing a meta-analysis.

Study Design. We searched for trials in Embasem, Cochrane Library, Embase, and Medline for studies that compared the effect of PENTO with those of other treatment methods. The usage of oxygen-free was chosen as the index of effectiveness. The Cochrane Collaboration's tool was used to assess the methodological quality of the trials.

Results. We identified 3 trials, which included 344 patients in the PENTO group and 340 patients in the "other treatment methods" (OTHER) group, and we performed a meta-analysis by using the random effect model. PENTO had a better effect compared with OTHER in the treatment of ORNJ, with a pooled odds ratio (OR) of 1.74 (95% CI, 1.19–2.53; P = .01). The pooled OR was 1.74 (95% CI, 1.19–2.53; P = .01). PENTO was statistically different from and treatment (OR = 2.02; 95% CI, 1.24–3.21; P = .01) and hyperbaric oxygen therapy (OR = 2.06; 95% CI, 1.74–2.03; P = .01) in terms of treatment effect. However, we could not conclude that PENTO was more effective than local surgery (OR = 0.50; 95% CI 0.80–3.00; P = .1).

Conclusions. The results of this meta-analysis suggest that the application of PENTO for the treatment of ORNJ shows superior efficacy relative to the other treatment methods. (Oral Surg Oral Med Oral Path Oral Radiol 2020;129:207-214)

Osteoradionecrosis of the jaws (ORNJ) is a common complication after radiotherapy for head and neck tumors.[1] The incidence of ORNJ is 5% to 15%, and it occurs in 70% of the patients within 5 years after radiotherapy.[2,3] Once ORNJ develops, patients frequently have severe symptoms, including pain, bone exposure, fistula, bone expansion, or even pathologic fractures.[4,5]

However, because only a few studies have assessed the effect of PENTO and because the results of these studies were not the same, the effect of PENTO is still being debated and not widely recognized. Some studies have explored the principles and the application procedures of PENTO in ORNJ treatment. Some studies also review analyzed the difference between the effect of PENTO and those of other therapies.

The aim of this meta-analysis was to explore the differences between the effects of PENTO and other combined or single treatments, and to provide a more prominent for wider application of PENTO in clinical practice.

PARTICIPANTS AND METHODS

Search Strategy

This meta-analysis was performed according to the Preferred Reporting Items for Systematic Reviews and Meta-analyses guidelines. The following electronic databases and citation indices were searched: PubMed, Cochrane Library, Embase, and Medline with the search terms for each database published until 31 December 2019 to those any language restrictions. The general

Statement of Clinical Relevance

This meta-analysis demonstrates limited evidence to support the application of combined pentoxifylline (PE) plus vitamin E in the treatment of osteoradionecrosis of jaws. This treatment demonstrated greater effectiveness compared with alternative treatments with use of antibiotics or hyperbaric oxygen therapy.

Zhang Z, *et al.* Oral Surg Oral Med Oral Path Oral Radio 2020;129

Available online at www.sciencedirect.com

British Journal of Oral and Maxillofacial Surgery 52 (2014) 386–392

211-310

Changing trends and the role of medical management on the outcome of patients treated for osteoradionecrosis of the mandible: experience from a regional head and neck unit

J. D'Souza*, D. Lowe, S.N. Rogers

*Regional Head and Neck Unit, Royal Liverpool University Hospital, Prescot Street, Liverpool L7 8XP, UK
† Evidence-based Practice Research Centre (EPRC), Alan Gill University, UK

Accepted 5 January 2014
Available online 25 January 2014

Abstract

This study is a retrospective review of treatment outcomes of osteoradionecrosis (ORN) of the mandible with specific reference to the evolving role of medical management with pentoxifylline, tocopherol, and doxycycline. We reviewed the presentation and management of 72 patients with ORN of the mandible treated at a regional head and neck unit between 1 January 1990 and 31 December 2011. Patients were grouped according to the Marx classification: grade 1 (n = 36), grade II (n = 16), and grade III (n = 22). Twelve patients with grade I ORN, 3 with grade II, and 19 with grade III, were prescribed medical treatment. Of these, three with grade I and two with grade II ORN were cured, and the remaining patients underwent surgery. Medical treatment improved the outcome in patients with grade I ORN (p = 0.0001). Patients with failed conservative management were further analysed for the need for free flap reconstruction. Medical management was introduced as a standard treatment in January 2006. Of the 26 patients diagnosed before this, 20 (77%) required resection and free flap reconstruction, compared with 8 (42%) of the 19 patients diagnosed after this (p = 0.0001). Medical management improved the outcome of patients with ORN of the mandible, and reduced the need for free flap reconstruction. Medical management was introduced as a standard treatment in January 2006. Of the 26 patients diagnosed before this, 20 (77%) required resection and free flap reconstruction, compared with 8 (42%) of the 19 patients diagnosed after this (p = 0.0001).

© 2014 The British Association of Oral and Maxillofacial Surgeons. Published by Elsevier Ltd. All rights reserved.

Keywords: Osteoradionecrosis; Pentoxifylline; Tocopherol; Doxycycline; Hyperbaric oxygen therapy; Medical management; Survival

Introduction

Osteoradionecrosis (ORN) occurs over a long time, but 70–94% of cases have been reported to develop within the first 3 years after radiotherapy.[1,2] The reported incidence of ORN ranges from 2% to 22%.[3–5] The aetiology of ORN is multifactorial and ORN has a varied presentation ranging from mild asymptomatic disease to severe pain, fistulae, suppuration, exposed bone, and pathological fracture. Conservative management has traditionally involved minimal surgical debridement and antibiotics, and ORN has been treated with conservative medical management with pentoxifylline, tocopherol, and clodronate has been introduced. Patients with aggressive ORN often require radical resection and free flap reconstruction to achieve a satisfactory outcome.

Tumour factors, treatment factors and patient factors influence the outcome of operative by promoting angiogenesis in irradiated tissues.[6,7] but some authors have reported good outcomes with surgery alone.[8] A meta-analysis of treatment options by Lyalina et al.[9] showed that HBOT is not better than placebo, and they raised concerns about its damaging effects. Given the equivocal evidence, there is a lack of enthusiasm among maxillofacial surgeons in the UK to prescribe a prophylactic course of HBOT before dental extractions. Improvement of the pathophysiology of ORN based on the concept of radiation-induced fibrosis has allowed the introduction of medical management comprising pentoxifylline, tocopherol, and clodronate.

Table 5
Treatment and outcomes in patients with osteoradionecrosis (ORN) before and since 2006.

	Before 2006				Since 2006			
	Debridement (n = 12)	HBOT (n = 29)	Medical (n = 2)	Total (n = 30)	Debridement (n = 6)	HBOT (n = 3)	Medical (n = 2)	Total (n = 32)
ORN grade:								
I	3	7	–	10	1	2	12	10
II	4	7	–	11	1	1	3	5
III	5	15	2	18	–	–	6	9
ORN outcome of conservative management:								
Healed	5	4	–	9	–	–	3	5
Stable	3	11	1	12	–	–	2	11
Progressive	6	15	1	26	3	3	7	13
Free-flap surgery	6	12	1	20	1	2	4	8
ORN outcome after free-flap surgery:								
Healed	5	6	1	12	1	2	4	7
Non union	1	–	–	1	–	–	–	–
Stable	–	6	–	6	–	–	4	4
ORN	–	1	–	1	–	–	1	1
ORN outcome (at death or 1.10.11):								
Healed	10	10	1	21	1	2	11	14
Non union	1	–	–	1	–	–	–	–
Stable	1	8	1	10	4	1	10	15
ORN	1	7	–	7	1	–	2	3
Locoregional recurrence	1	7	–	8	1	–	3	4
Locoregional recurrence after free-flap surgery	1	3	–	4	–	–	–	–

HBOT: hyperbaric oxygen therapy.

D'Souza J, *et al.* B J Oral Maxillo Surg 2014;52

Trials

211-507

STUDY PROTOCOL — Open Access

RAPTOR: Randomised Controlled Trial of PENTOCLO (pentoxifylline-tocopherol-clodronate) in Mandibular Osteoradionecrosis—study protocol for an open-label phase II randomised controlled superiority trial

Richard Shaw*, Ruth Knight, Ayten Basoglu, Mandeep Bajwa, Julie Perry, Anastasios Karatas, Stefano Pedevè, Vincent Killer, Rebecca Tangney, Chris Butterworth, James McCaul, Jagtar Dhindsa, Vinod Patel, Mereid Evans and Richard Jackson

Abstract

Background: Mandibular osteoradionecrosis (ORN) is a severe late radiation toxicity affecting 5–15% of patients who have received radiotherapy as part of treatment for head and neck malignancy. ORN can cause severe disfigurement, dysfunction, pain and infection. There remains little robust evidence supporting the efficacy of medical or surgical management currently offered in clinical practice. Retrospective case series and meta-analyses of observational studies suggest that a repurposed triple drug combination pentoxifylline-tocopherol-clodronate (PENTOCLO) may be effective in preventing deterioration, promoting healing and ultimately reducing the need for major reconstructive surgery.

Methods: The RAPTOR trial is a phase II, open-label, multicentre randomised controlled trial with a superiority design. Eligible subjects with mandibular ORN are randomised 1:1 to receive standard of care (SoC) or 6 PENTOCLO plus standard of care (SoC) for 12 months. The primary outcome measure is time from randomisation to healing of ORN (without the need for surgery), as measured by clinical examination (confirmed by completely healed oral mucosa), intra-oral clinical photographs and imaging. RAPTOR has an embedded translational sample collection and a methodological component exploring the use of electronic patient-reported outcome measures (ePROM).

Discussion: The RAPTOR trial is the first randomised controlled clinical trial of PENTOCLO in this clinical setting. The results of this phase II trial will provide robust preliminary evidence on its efficacy and inform the feasibility and sample size estimates of a subsequent definitive RCT.

Shaw R, *et al.* Trials 2025;26:254

Article original

Partie III : les lambeaux libres périostés dans le traitement des ostéoradionécroses mandibulaires

Part III: Free periosteal flaps as a treatment for mandibular osteoradionecrosis

C. d'Hauthuille*, C. Nadiri†, F. Farès‡, G. Siler§, B. Devauchelle*

*Service de chirurgie maxillofaciale et stomatologie, CHU de Nancy, place Alain Bernheim, 54000 Nancy, France
† Service de chirurgie maxillofaciale et stomatologie, CHU Gabriel-Montpied, place Henri-Dunant, 63003 Clermont-Ferrand, France
‡ Service de chirurgie maxillofaciale et stomatologie, CHU Gabriel-Montpied, place Henri-Dunant, 63003 Clermont-Ferrand, France
§ Service de chirurgie maxillofaciale et stomatologie, CHU Gabriel-Montpied, place Henri-Dunant, 63003 Clermont-Ferrand, France

Disponible en ligne sur www.sciencedirect.com

Résumé

Introduction. Le lambeau libre périosté transporte un tissu non atrophié, capable de non-ostéogenèse, d'ostéo-induction et d'ostéo-conduction. Il permet de reconstruire des pertes de substance mandibulaires d'emblée ou secondaires après ostéoradionécrose. L'auteur rapporte ses résultats par rapport aux techniques traditionnelles.

Matériel et méthodes. Entre 2000 et 2010, 7 patients (3 hommes et 4 femmes) ont bénéficié d'un lambeau libre périosté pour ostéoradionécrose mandibulaire, dans les 20 ans d'antécédentes mandibulaires après irradiation pour un carcinomes oro-pharyngiens. Le diagnostic de ostéoradionécrose a été porté sur des signes cliniques et radiologiques. Le lambeau libre périosté a été prélevé sur le membre inférieur, associé à un lambeau fibulaire ostéocutané pour reconstruire la mandibule. Le lambeau a été clamé et mobilisé. Le pédicule vasculaire a été anastomosé sur les vaisseaux cervicaux.

Résultats. Deux patientes évolutives ont été secourues chez les patients qui étaient ostéoradionécrose de grades 2 et 3 selon la classification de Marx. Les patients ont été suivis en moyenne 2 ans. Le lambeau libre périosté transporte un tissu non atrophié. Le ostéosynthèse a été satisfaisante sur le plan fonctionnel et esthétique. Une ostéoporoseline a été constatée pour deux patients du lambeau fibulaire.

Discussion. Le lambeau de patients consolidé est une solution thérapeutique de l'ostéoradionécrose diffuse. C'est une alternative à la chirurgie conventionnelle, à la chirurgie de reconstruction, à une fonction ostéo-inductrice, ostéogénique et de conduction des cellules ostéogènes, ostéoblastogenèse et histiocytogenèse. Le lambeau libre périosté est une solution intéressante.

© 2008 Elsevier Masson SAS. Tous droits réservés.

Mots-clés : Ostéoradionécrose, Lambeau, Microchirurgie, Fibrose

d'Hauthuille,C *et al.* Review de Stomatologie et de Chirurgie Maxillo-Faciale 2009;110(1)

Available online at www.sciencedirect.com

British Journal of Oral and Maxillofacial Surgery 57 (2019) 250–256

211-442

Treatment of mandibular osteoradionecrosis by periosteal free flaps

J. Bettoni*,†,‡, M. Oliverio*,†,‡, J. Duisit§,¶, A. Cauhé*,†, G. Bruzzi*,†, B. Lengele||,#, S. Teixeira*,†, S. Dakpé*,†,‡, B. Devauchelle*,†,‡

*Department Maxillo-Facial Surgery, University Hospital of Amiens, Amiens, France, 80054 Amiens, France
† Jules Verne University of Picardy, 80000 Amiens, France
‡ Department of Plastic and Reconstructive Surgery, University-Laboratory of Lorraine-Grenoble, Service Jeanne Hyacinthe, 29 Boulevard Jean-Moulin, 38000 Grenoble, France
§ Department of Plastic and Reconstructive Surgery, University-Laboratory of Lorraine-Grenoble, Service Jeanne Hyacinthe, 29 Boulevard Jean-Moulin, 38000 Grenoble, France
¶ Department of Plastic and Reconstructive Surgery, University-Laboratory of Lorraine-Grenoble, Service Jeanne Hyacinthe, 29 Boulevard Jean-Moulin, 38000 Grenoble, France
|| Department of Plastic and Reconstructive Surgery, University-Laboratory of Lorraine-Grenoble, Service Jeanne Hyacinthe, 29 Boulevard Jean-Moulin, 38000 Grenoble, France
Department of Plastic and Reconstructive Surgery, University-Laboratory of Lorraine-Grenoble, Service Jeanne Hyacinthe, 29 Boulevard Jean-Moulin, 38000 Grenoble, France

Accepted 19 January 2018
Available online 14 May 2018

Abstract

Mandible osteoradionecrosis (ORN) is one of the most serious complications of radiotherapy of the head and neck, with a detrimental impact on functional and aesthetic outcomes. Periosteal free flaps have an angiogenic, osteoinductive, osteogenic, osteoconductive and osteoblastogenic potential. The aim of this study was to evaluate the outcomes of patients treated for mandibular ORN using periosteal free flaps. We reviewed a single center retrospective study between 2003 and 2015 and recalled the management of 7 patients (4 women and 3 men) who were being treated for mandibular ORN using a free periosteal flap associated with a free fibular flap. The mean follow-up was 2 years. Two patients underwent hemicolectomy and bilateral neck dissection, and two underwent neck dissection. Osteosynthesis was performed using a reconstruction plate in 5 patients, and bone grafts were performed in 7 patients. Two patients were treated for recurrent osteoradionecrosis. Two patients were treated for a second osteoradionecrosis. Two patients underwent a second free flap. Two patients underwent a second free flap. Two patients underwent a second free flap

JAMA Otolaryngology–Head & Neck Surgery | Original Investigation 211-503

Evaluation of Anterolateral Thigh Fascia Lata Rescue Flap for Mandibular Osteoradionecrosis

Notani Stages

1. ORN confined to alveolar bone
2. ORN limited to alveolar bone and/or above level of inferior alveolar canal
3. ORN under lower part of inferior alveolar canal, with fistula or bone fx.

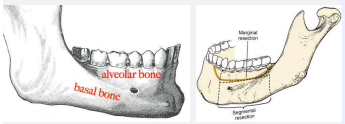

Arianpour K, *et al.* JAMA Otol Head Neck Surg 2023;149(7):621-627

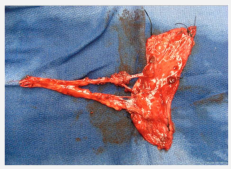

50/52 MORN cases successfully managed

2 progressed to fibular free flap

Simple, reliable, low risk

Low donor site morbidity - ease of harvest

Curr Treat Options in Oncol (2021) 22: 79 211-492

Overview and Emerging Trends in the Treatment of Osteoradionecrosis

Joseph B. Melacy MD, Emily Zheng MD, Michael A. Fritz MD, Peter J Dziuk MD

Hyperbaric Oxygen Therapy

Standard procedure: *Pressures often vary between 2.0 & 2.5 ATA for 60-120 minutes once or twice daily for 30-60 sessions*

Contraindications: *Tumor recurrence; history of HBO complications*

Complications: *Tumor recurrence (theoretical, not substantiated by evidence); visual disturbance, barotrauma, oxygen toxicity*

Special points: *Evidence for HBO treatment & prevention of ORN mixed. Smaller uncontrolled studies have shown recovery with HBO alone or combined with surgery, however, few randomized controlled trials exist. The first showed ORN prevention for dental procedures. Subsequent RCTs have not supported HBO treatment or prevention efficacy. Cochrane Review suggested moderate-quality evidence for increased likelihood to achieve mucosal coverage & prevent post-op breakdown.*

Cost-effectiveness: *Expensive (often more expensive that surgery given number of visits required and cost of equipment/staffing).*

Meleca JB, *et al.* Curr Treat Options in Oncol 2021;22

211-470

Fasciocutaneous Flaps for Refractory Intermediate Stage Osteoradionecrosis of the Mandible—Is It Time for a Shift in Management?

"Marx pioneered HBO, no RCTs have replicated his results"
"Appears little benefit to addition of HBO for advanced stages"

Concept of RT-induced fibro-atrophic theory
Use of PENTO/PENTOCLO promising - better data required

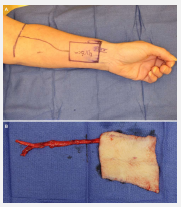

Gigliotti J, *et al.* J Oral Maxillofac Surg 2021;79

211-472

Critical Review

Osteoradionecrosis: Exposing the Evidence Not the Bone

"The microvascular osteo-myo-cutaneous free flap, such as free fibular flap, has evolved to become a workhorse …"

"Conservative management including the use of pentoxifylline-vit. E should be attempted before surgical procedures"

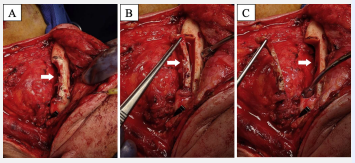

Frankart AJ, *et al.* Int J Rad Oncol Biol Phys 2021;109(5)

Oral Oncology 211-475

Safety of boneless reconstruction of the mandible with a CAD/CAM designed titanium device: The replica cohort study

18 pts over 5 yrs

Primary outcomes at 1 yr. achieved in 14/18 (78%)

absence of extrusion
decrease/cessation of pain
stability/increase in mouth opening
resumption of oral feeding
absence of fracture/displacement/screw loosening

MRONJ - 10 ORN - 2 SCC - 2 Other - 4

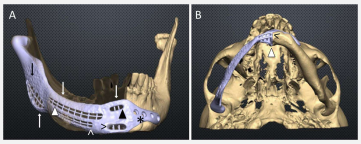

Bedogni A, *et al.* J Oral Oncology 2021;112

Marx Stage II:

Stage I "non-responder"

Local surgical debridement or resection

10 HBO treatments post-operatively

Marx Stage III/III-R:

Extensive mucosal loss & more necrotic bone

Soft tissue fistula; pathologic fracture; bone resorption; Stage II non-responder

Following initial 30 treatments:

Partial jaw resection; fixation; primary closure of any fistulae

Resection of RT damaged soft tissue & skin flap repair

Ten additional treatments

10-12 weeks after resection > formal reconstruction

Titanium fixation plate; titanium/Dacron tray-filled cancellous bone chips

+/- ten additional treatments

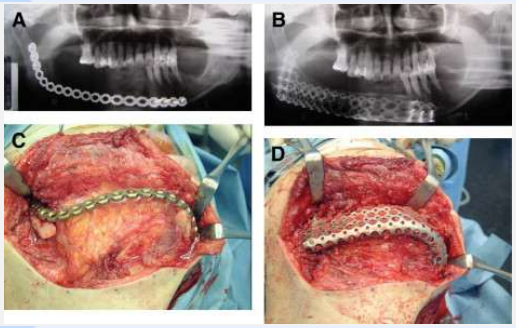

Prospective study; complications within irradiated soft tissue

> 6,400 cGy

Wound Infections	N	Minor	Major	Total	
Non-HBO	80	6 (7.5%)	13 (16%)	19 (24%)	
HBO	80	3 (3.5%)	2 (2.5%)	5 (6%)	*P= 0.001*

Wound Dehiscence	N	Minor	Major	Total	
Non-HBO	80	12 (15%)	26 (33%)	38 (48%)	
HBO	80	6 (7.5%)	3 (3.5%)	9 (11%)	*P= 0.001*

Delayed Healing	N		
Non-HBO	80	44 (55%)	
HBO	80	9 (11%)	*P= 0.005*

Marx, RE 1994
In: Hyperbaric Medicine Practice



JOURNAL OF CLINICAL ONCOLOGY — ORIGINAL REPORT

211-197

Hyperbaric Oxygen Therapy for Radionecrosis of the Jaw: A Randomized, Placebo-Controlled, Double-Blind Trial From the ORN96 Study Group

ABSTRACT

INTRODUCTION

Annane D, *et al.* J Clinical Oncology 2004;22(24)

Study design

134 consecutive ORN pts assessed
12 centers; 1997-2001

68 randomized & analyzed
31 HBO - 37 sham

Study stopped at 2nd interim analysis

HBO 19% healed

Sham 32% healed

"Need for surgery = HBO failure"

UHM 2019; VOL. 46 NO. 4 – HBO$_2$ AND OSTEORADIONECROSIS: COMMENTARY

211-432

EDITORIAL COMMENTARY

Challenges threaten, opportunity awaits hyperbaric medicine and the head and neck cancer patient

Richard Clarke, CHT

National Reconstructive Services, Columbia, South Carolina, U.S.

ABSTRACT

Clarke R. UHM 2019;46(4)

UHM 2019; VOL. 46 NO. 4 – HBO$_2$ AND OSTEORADIONECROSIS: COUNTERPOINT COMMENTARY

211-443

EDITORIAL COMMENTARY

Hyperbaric oxygen is still needed in the management and prevention of mandibular necrosis: a response to Mr. Richard Clarke

Robert E. Marx, DDS[1], John J. Feldmeier, DO[2], Robert P. Johnson, DDS[2]

ABSTRACT

INTRODUCTION

DISCUSSION

Marx RE, *et al.* UHM 2019;46(4)



211-434

Synchronous Reconstruction of a Total Mandibulectomy Defect With a Single Fibula Osteocutaneous Free Flap

*Ramsey Turner, DDS, *J. Marshall Green III, DDS,† Daniel Winslow, DDS,† and Andre Goshen, DDS‡*

Osteoradionecrosis (ORN) is a well-known and sizable late complication of radiation therapy to the craniofacial skeleton. Although this therapy can be life-saving, it also produces tissue toxicity in epithelial and connectival tissues in an acute and chronic fashion. In the most severe cases of ORN, such as the one presented in this report, bilateral disease results in the need for total mandibulectomy and creates a tremendous reconstructive challenge. The selection of microvascular surgery and free tissue transfer for the reconstruction of mandibular defects has been well established. This report describes a unique case of total mandibulectomy with synchronous reconstruction using a single vascularized fibula osteocutaneous flap with subsequent dental implant reconstruction and prosthetic rehabilitation.

© 2018 The American Association of Oral and Maxillofacial Surgeons

J Oral Maxillofac Surg 76:2128-e2128-e, 2018

A multimodality approach to the management of complex, large, challenging defects has brought the cancer-free survival rate to 85%. With radiotherapy (RT) playing a possible therapeutic role in every stage of oropharyngeal cancer, the management of these patients is a primary concern, the number of patients exposed to ionizing radiation for therapeutic purposes is considerable. Head and neck cancers are treated with radiation doses higher than 120 Gy. Although this dosage can be life-extending, it also produces tissue toxicity in epithelial and connective tissues in an acute and chronic fashion. Osteoradionecrosis (ORN), a chronic radiation toxicity of bone, is a late complication of RT. This results in hypovitalism, hypovascular, and hypoxic conditions that leave the mandible susceptible to necrosis and secondary infection. The Veterans Hospital Radiation Oncology Study Group 73-05 (RTOG 73-05) was an randomized blind study, 3 dosage, and geometry to the radiation field lower is susceptible to bilateral ORN. The incidence of ORN ranges from 2% to 15% of patients with oropharyngeal cancer who received RT.[1] Despite the promised dose-sparing of the mandible, ORN remains a risk for RT, with life-threatening and long-lasting late effects of radiation poisoning.[2]

Tursun R, *et al.* J Oral Maxillofac Surg 2018;76

211-479

Radiotherapy and Oncology

Hyperbaric oxygen treatment of mandibular osteoradionecrosis: Combined data from the two randomized clinical trials DAHANCA-21 and NWHTZ0809-1

Forner L, *et al.* Radiation & Oncology 2022;166

Study design

97 ORN pts randomized
12 centers; 2008-2017

Required removal necrotic bone
"some pts reconstructed"

Randomly assigned per ITT
51 Surg. + HBO vs. 46 Surg.

Primary outcome: ORN healing 1 yr.

70% Surg + HBO vs. 51% Surg.

"HBO did not significantly improve healing…"

"This effect not statistically significant"

Modern management mandibular reconstruction

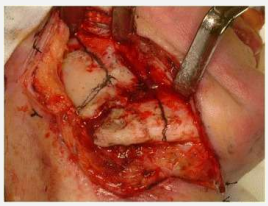

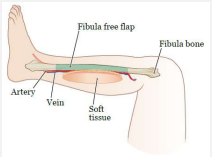

APS Archives of Plastic Surgery

211-466

Mandibular Reconstruction Using the Free Vascularized Fibula Graft: An Overview of Different Modifications

George Kokosis, Robin Schmitz, David B. Powers, Detlev Erdmann

Keywords Mandibular reconstruction / Fibula / Microsurgery

INTRODUCTION

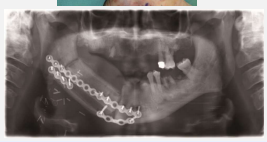

Kokosis G, *et al.* Arch Plastic Surg 2016;43(1)

ASCO Special Articles

211-499

Prevention and Management of Osteoradionecrosis in Patients With Head and Neck Cancer Treated With Radiation Therapy: ISOO-MASCC-ASCO Guideline

ABSTRACT

ACCOMPANYING CONTENT

" The use of hyperbaric oxygen in prevention and management of ORN remains largely unjustified, with limited evidence to support its practice"

Peterson DE, *et al.* J Clinical Oncology 2024;May 1



State of the Art Review

211-502

AMERICAN ACADEMY OF OTOLARYNGOLOGY–HEAD AND NECK SURGERY FOUNDATION

Check for updates

Otolaryngology–Head and Neck Surgery 2024, Vol. 00(00) 1–13 © 2024 The Author(s) Otolaryngology–Head and Neck Surgery is published by Wiley Periodicals LLC on behalf of American Academy of Otolaryngology–Head and Neck Surgery Foundation. This article is a U.S. Government work. https://doi.org/10.1002/ohn.711 http://wileyonlinelibrary.com/journal/ohn WILEY

Managing Mandibular Osteoradionecrosis

Michael A. Fritz, MD, Khashayar Arianpour, MD, Sara W. Liu, MD, Eric D. Lamarre, MD, Dana J. Gunther, MD, Peter J. Ciolek, MD, Patrick J. Byrne, MD, and Brandon L. Prendes, MD

Abstract

Objective. Mandibular osteoradionecrosis (MORN) is a morbid complication of head and neck radiation therapy. Recent advances in surgical and medical therapies underscore the need for a shift in traditional treatment paradigms and a disease grading system that can guide appropriate management.

Data Sources. PubmedMEDLINE.

Review Methods. We conducted a detailed review of publications related to MORN, specifically focusing on its staging and management mechanisms. Articles meeting inclusion criteria were synthesized into a final narrative review.

Conclusion. There has been a paradigm shift away from conservative management of advanced disease, with mounting evidence for the efficacy of aerobiotherapy and nonoptimal in early-stage disease and novel surgical methods to manage moderate and late-stage disease warrant an updated staging classification which is proposed.

Implications for Practice. This review summarizes the clinical efficacy of established and novel therapeutic modalities currently available in treating MORN, emphasizing the significant advancements in treating late-stage MORN. It introduces a comprehensive staging system that incorporates disease progression, traditional, evidence-supported surgical and medical management with effective early intervention strategies.

Keywords

free flap, head and neck, jaw, mandible, microsurgery, osteoradionecrosis, reconstruction, revision flap, staging

Received May 2, 2024; accepted September 14, 2024.

Mandibular osteoradionecrosis (MORN) is a dreaded late complication of radiation therapy utilized in the treatment of head and neck cancer. It carries a progressive course that ultimately leads to significant morbidity and negatively impacts quality of life. Patients may present for trauma, oroantral

antibiotics and repeated debridement. End-stage disease manifests as full-thickness progression resulting in orocutaneous fistulas and nonhealing pathologic fractures with mandibular and/or masticator dysfunction. To date, treatment of MORN has been challenging and has evolved from a single-stage approach to one that depend on the presenting disease stage and prior failed therapeutic attempts. Early and moderate-stage osteoradionecrosis (ORN) have been traditionally managed through various modalities, including product oral care, pentoxifylline-tocopherol-clodronate (PENTOCLO) treatment or nonresection, and hyperbaric oxygen therapy (HBOT). Late-stage ORN requires segmental resection and free tissue microvascular reconstruction with osteocutaneous flaps which, although effective, incur significant morbidity and impact quality of life.

Substantial evidence has emerged evaluating some available treatment options for MORN, including targeted medical therapies and early intervention, low-morbidity surgical techniques. Long-term efficacy has been demonstrated in early-stage disease treated with hyperbaric oxygen and in late-stage disease treated with free flaps. Moreover, prospective clinical trials have contested the efficacy of HBOT. These new findings have challenged the traditional approach to treating ORN. The purpose of this study is to conduct a comprehensive review of all existing literature on patients with MORN, and evaluate the efficacy of current treatment options, both medical and surgical, and their impact on staging and treatment algorithms in the contemporary era.

Methods

A comprehensive search was performed in the PubMed/MEDLINE databases for all existing literature up to September 8, 2024, on any English literature pertaining to

Division of Facial Plastic and Microvascular Surgery, Head and Neck Institute, Cleveland Clinic, Cleveland, Ohio, USA

Corresponding Author:
Michael A. Fritz, MD, Division of Facial Plastic and Microvascular Surgery, Cleveland Clinic, 9500 Euclid Avenue, Cleveland, Ohio 44195, USA.

This is an open access article under the terms of the Creative Commons Attribution-NonCommercial-NoDerivs License, which permits use and distribution in any medium, provided the original work is properly cited, the use is non-commercial and no modifications or adaptations are made.

Fritz MA, *et al.* Otolaryn Head Neck Surg 2024;00:1-13

Where does HBO currently stand for ORN?

Stage I - localized

- Four decades clinical practice experience c/w Marx protocol
- Widely, although not exclusively reimbursed
- Not supported by efficacy/effectiveness evidence
- PENTOCLO <100 reported cases; no efficacy evidence
- Recent limited reporting of periosteal & ALT/FFF flaps promising

Weight of existing evidence supports HBO **

** Cochrane Database of Systemic Reviews, 2016

Stage III 'advanced'

Introduction of Marx Protocol (1983) mandible reconstruction
- *~ HBO reduced failure rates; optimized healing*
- *~ essential standard of care ~ two decades*

Advent of microvascular surgery another step change

Single-stage radical resection & myo-cutaneous free fibular flap
- *~ now considered "gold standard" for advanced ORN since 2000*
- *~ HBO occasionally employed for post-op complications*

Marx two-stage protocol in absence of microvascular surgeon

217-006

ARTICLES

Post-irradiation dental care involving means to tissue can require a costly prophylactic measure.

Prevention of osteoradionecrosis: a randomized prospective clinical trial of hyperbaric oxygen versus penicillin

Marx RE, *et al.* JADA 1985;111:49-54

- 74 pts randomized to HBO or PCN
- All high risk > 6,000 cGy
- 135 teeth extracted in 37 PCN pts
  - *~ 29.9% unhealed sockets at 6 months*
- 156 teeth extracted in 37 HBO pts
  - *~ 5.6% unhealed sockets at 6 months*

ORN prophylaxis protocol

Basis for 20 pre-op. procedures

angiogenesis plateau

Basis for 10 post-op. procedures

reduces dehiscence by promoting collagen production along incision lines



217-047

Clinical Investigation

HOPON (Hyperbaric Oxygen for the Prevention of Osteoradionecrosis): A Randomized Controlled Trial of Hyperbaric Oxygen to Prevent Osteoradionecrosis of the Irradiated Mandible After Dentoalveolar Surgery

Shaw, RJ, *et al.* Int J Rad Oncol Bio Phys 2019

- 144 pts randomized; HBO vs. no HBO
- 10 facilities
- 55 received HBO + surgery
- 66 received surgery
- Mean RT dose 6,300 cGy
- Blinded assessors
- Trail halted at interim analysis
- Data relates to conformal/IMRT